Riv. It. Biol. Med., 7, 76-80, 1987

"Thymomodulin" in parodontal bone surgery

FR. DAJBUKAT Jr., Z. URAY, D. POP, E. MINCIONE*, C. RUOZI, B. PALMIERI**

Riv. It. Biol. Med., 7, 76-80, 1987

"Thymomodulin" in parodontal bone surgery

FR. DAJBUKAT Jr., Z. URAY, D. POP, E. MINCIONE*, C. RUOZI, B. PALMIERI**

Summary - Riassunto - Résumé

A clinico-radiologic study was performed on thymomodulin, a deproteinized calf thymus derivative. The substance exerts an immunomyeloregenerating action in parodontal bone surgery. On the ground of the positive clinico-experimental results reported by the Oncologic Institute of Cluj-Napoca with the use of thymomodulin following radiation therapy in malignant tumors, with which hematologic and leukocyte regeneration was obtained, the Authors used this substance post-operatively in 15 clinical cases of deep chronic marginal parodontopathy with bony pouches and dental mobility. The bony pouches in vertical atrophy were resolved by combining the 3 techniques described by Friedmann and Nebers, that is, osteotomy, osteoplasty and medullo-spongy bone autogenic transplant. Routine laboratory findings and periodical radiographies carried out in patients having undergone surgery for parodontopathy, given i.m. thymomodulin postoperatively (20 mg) for 10 days, showed more rapid remineralization of the limbus alveolaris, undisturbed integration of the medullo-osseous autogenic transplant and better gingival reattachment as compared to the controls. Control of the allergic component and modulation of the reticulo-endothelial system were confirmed by disappearance of the inflammatory syndrome. The positive clinical and radiologic results obtained on follow-up 1, 2 and 3 years following parodontal bone surgery combined with administration of thymomodulin, open new perspectives for the use on a wide scale of this immunomyeloregenerating substance in dentomaxillary surgery.

KEY WORDS.—Thymomodulin - Parondontal bone surgery - Parodontopathy.

È stato condotto uno studio clinico-radiologico sulla timomodulina, un derivato di timo di vitello deproteinizzato. Il prodotto esercita un'azione immunomielorigeneratrice nella chirurgia ossea periodontale. Sulla base dei risultati clinico-sperimentali positivi riportati dall'Istituto Oncologico di Cluj-Napoca con l'uso di timomodulina in corso di radioterapia per tumori maligni, con una rigenerazione ematica e leucocitaria, gli Autori hanno usato questa sostanza dopo l'intervento chirurgico in 15 casi clinici di periodontopatia cronica profonda con sacche ossee e mobilità dentale. Le tasche ossee con atrofia verticale, sono state risolte combinando le 3 tecniche descritte da Friedmann e Nebers, cioè l'osteotomia, l'osteoplastica e l'auto-trapianto di osso spugnoso. I dati di laboratorio e le radiografie periodiche effettuate in pazienti sottoposti a chirurgia per periodontopatia, trattati con timomodulina (20 mg) i.m. per 10 giorni dopo l'intervento chirurgico, hanno mostrato una più rapida remineralizzazione del limbus alveolaris, l'integrazione normale dell'auto-trapianto osseo ed un migliore riattacco gengivale in confronto ai controlli. La scomparsa dell'infiammazione ha confermato il controllo della componente allergica e la modulazione del sistema reticolo-endoteliale. I risultati clinici e radiologici positivi ottenuti 1, 2 e 3 anni dopo la chirurgia ossea periodontale combinata con la somministrazione di timomodulina, aprono nuove prospettive all'uso su larga scala di questa sostanza immunomielorigeneratrice in chirurgia dentomascellare.

PAROLE CHIAVE.—Timomodulina - Chirurgia ossea periodontale - Periodontopatia.

On a effectué une étude clinique-radiologique de la thymomoduline, dérivé déprotéiné de thymus bovin. Cette substance a un effet immunisant et myélorégénérateur lors de chirurgie ostéo-paradentaire. Sur la base des bons résultats clinico-expérimentaux rapportés par l'Institut Oncologique de Cluj-Napoca, après utilisation de thymomoduline en cours de radiothérapie pour tumeurs malignes, avec laquelle on avait obtenu la régénération sanguine et leucocytaire, les Auteurs ont utilisé cette substance après opération chez 15 cas de paradontopathie chronique profonde avec saccules osseuses et mobilité dentaire. Les saccules osseuses avec atrophie verticale ont été résolues par l'association des 3 techniques de Friedmann et Nebers c-à-d., ostéotomie, ostéoplastie et auto-transplantation de os spongieux. Les routiniers examens de laboratoire et les radiographies périodiques effectués chez des patients soumis à opération chirurgicale pour paradontopathie et ayant reçu thymomoduline i.m. après l'intervention (20 mg pour 10 jours) ont montré une plus rapide reminéralisation du limbus alveolaris, l'intégration tranquille de l'auto-transplantation médullo-osseuse et un meilleur rattachement gingival par rapport aux contrôles. La disparition de l'inflammation a confirmé que la composante allergique avait été contrôlée. Les contrôles cliniques et radiologiques à 1, 2 et 3 ans après opération chirurgicale associée à thymomoduline ont mis en évidence les propriétés immunisantes et myelorégénératrices de la substance.

MOTS CLEF.—Thymomoduline - Chirurgie ostéo-paradentaire - Parodontopatie.

Cluj District Methodological Center of Stomatology in Cluj-Napoca (Director: Dr. Fr. Dajbukat)
Oncological Institute of Cluj-Napoca (Director: Prof. Dr. Doc. I. Kirikuţa)
Clinica Odontoiatrica - Università di Pavia
* Clinica Odontoiatrica - Università di Modena
** Cattedra di Semeiotica Chirurgica e Insegnamento supplettivo di Chirurgia orale - Scuola di Odontoiatria - Università di Modena

Chronic parodontopathy, a social illness with an incidence nearly similar to that of dental caries during the last decades, faced the parondontologists, surgeons and researchers with certain unelucidated aspects concerning etiopathogeny but only modest results were obtained.
The peculiar curative-therapeutic questions appear in the evolutive, clinical phases and in post-clinical phases of tissue exhaustion, when of the numerous therapeutic methods only laborious parodontal interventions can be made such as gingivo-osteoplasties, bone homeo-autotransplantation, various gingival plasties, mucosa autotransplants described and systematized by Friedmann and Goldman under the name of «muco-gingival surgery».
These surgical interventions were completed by the application of medullo-osseous, spongious autogenic transplants (Boyne, Hiatt, Nabers, Nitescu) with the most favourable clinic-experimental results [6].
It is considered that in the process of alveolar neoosteogenesis a decisive role is played by the primitive medullary reticular cells with a polymorphous differential potential, with osteoforming, chondroforming, angiogenetic possibilities and final formation of connective fascicles [6].
This therapeutic surgical link is completed by local-biologic re-equilibration (selective polishing, functional occlusal-articular reequilibration, buccal showers, etc.) and biostimulating pre- and postoperative general treatment.
After reestablishment of parodontal homeostasis, contention of the clinical results should be made by horizontal immobilization with «Concise» reinforced oral runners or stabilizing conjoint pieces.
With the advent of endo-osseous implantology needle implants were applied using the method of dental transfixation (Scialom, Pruin, Schmeltz) obtaining vertical stabilization of the parodontal teeth showing advanced mobility in the frontal region [1, 3].
The pre- and postoperative biostimulating treatment represents a particularly important auxiliary link in the dystrophic-inflammatory forms of parodontopathy in evolutive stages as well as in purely endogenous parodontosis.
Improved positive clinical results have been known after administration of Vaduryl, Proneuryl, Alveolactiv, Osopan. During the last time the range of biostimulins was completed by Calcitonin-Armour which was administered with promising results in dysmetabolic osteoporosis and in parodontopathy [7].
Among thymus derivatives, before the obtention of thymosin by Goldstein in USA, Ellem (Milan, Italy) obtained thymomodulin (Leucotrofina) using an original method. This is a deproteinized derivatives of calf thymus with a high active polypeptide concentration. This preparation is indicated in primitive and secondary leukopenic syndromes, in antibody-genesis deficit, for the prevention of leukopenia following therapy with cytostatic agents, as an adjuvant and immunostimulant in viral and bacterial infectious diseases.
Thymomodulin is in the form of ampoules containing 10 and 20 mg. The drug can be administered daily in the form of intramuscular injections of 10 or 20 mg.

Aim of the paper

Starting from the positive clinical-experimental results obtained at the Oncological Institute in Cluj-Napoca (Prof. Dr. Doc. I. Kirikuţa, Dr. Z. Uray) in the use of thymomodulin following radiation therapy in malignant tumors, with hematopoietic lymphocytic and leukocytic regeneration, we applied this substance post-operatively in 15 clinical cases of deep marginal chronic parodontopathy with bone pouches and dental mobility. The bone pouches and vertical atrophies were resolved by the association of the 3 surgical techniques described by Friedmann and Nebers: osteoctomy, osteoplasty and spongious, medullo-osseous autogenous transplants.

Materials and methods

The investigations were made on 15 patients (4 females and 11 males) aged between 20 and 60 years. Two groups of patients were formed, in the first group being included patients with chronic deep marginal parodontitis in the clinical and post-clinical stage, with gingival-osseous pouches, vertical bone atrophy, dental mobility grade II/III with localization in the frontal and molar region (7 cases).
The second group included cases of mixed (dystrophic-inflammatory) parodontopathy, evolutive-stage: with gingival retraction, horizontal bone atrophy associated with desmodental phenomena, localized vertical osteolysis, horizontal vertical dental migrations, dental mobility degree II/III (8 cases).
The control group was formed of 5 cases of dystrophic-inflammatory mixed parodontopathies.

Laboratory paraclinical examinations

The selected subjects were investigated by laboratory tests to preclude other infectious foci. Then routine laboratory tests were performed (quantitative and qualitative blood analysis, red blood cell count, hemoglobin, sedimentation rate of the erythrocytes, leukogram, thrombocytes, etc.). Mandibular and maxillary panoramic radiographs as well as retroalveolar films were obtained in order to make the *evolutive radiologic diagnosis*.

Type of parodontal surgical intervention

After pre-operative preparation (hygienization, detartration, buccal showers) the type of osteo-muco-gingival intervention was selected:

— gingivo-osteoplasty, 15 cases;

— autogenous spongious-medullary bone transplants, 7 cases;

— apical resections, 3 cases;

— dental transfixation with Scialom needle implant, 8 cases;

— tooth extractions, 4 cases;

— gingivoplasties (obliquely rotated skin-graft-Gruppe-Waren, 4 cases).

The clinical cases operated upon were contentioned by horizontal, vertical immobilizations and conjoint works: uninforced palatinal Concise runners, 1 case; reinforced palatinal Concise runners, 10 cases; conjoint works (bridges), 4 cases; temporary immobilizations with vestibular splints, 5 cases; temporary immobilizations with «8» and «IVY» shaped ligatures, 3 cases; «U» (Schulman) splint, 3 cases; «L» splint, 3 cases.

Six representative clinical cases of operated chronic parodontopathy with bone pouches are presented in what follows.

Seven days after the parodontal surgical interventions in all the selected patients (group I and II)-thymomodulin 20 mg/day was administered in intramuscular injections for 10 days, after which the routine laboratory tests were performed.

The operated clinical cases were dispensarized and followed up clinically and radiologically. Thus comparative periodic radiographs were obtained every 6 months, following up the remineralization of the marginal alveolar limbs, stabilization of the process of bone atrophy and of halisteresis, reintegration of the applied medullo-osseous autogenous transplants and integration of the transfixing needle implants.

Results and discussion

The results of the routine laboratory tests obtained after administration of thymomodulin for 10 days in the 15 selected patients were compared with those of the control group and the significant differences were represented graphically on comparative diagrams against the mean levels.

A modulating effect of thymomodulin on the sedimentation rate of the erythrocytes and on leukocytosis was obtained in operated parodontopathy with bone pouches these parameters returned to the normal levels after a 10 days treatment with thymomodulin, showing reestablishment of the parodontal homeostasis, control of the inflammatory syndrome and parodontal defocalization (Fig. 1).

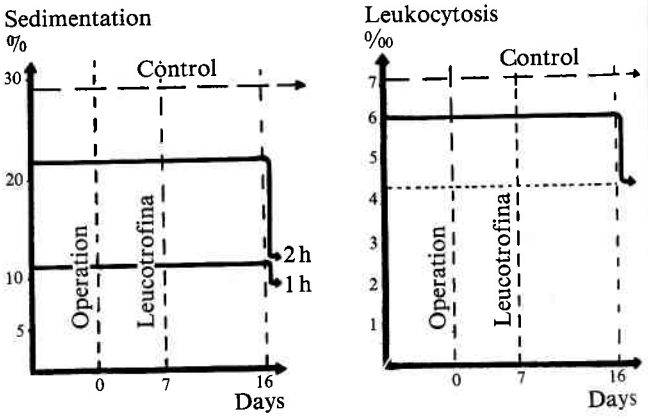

Fig. 1.

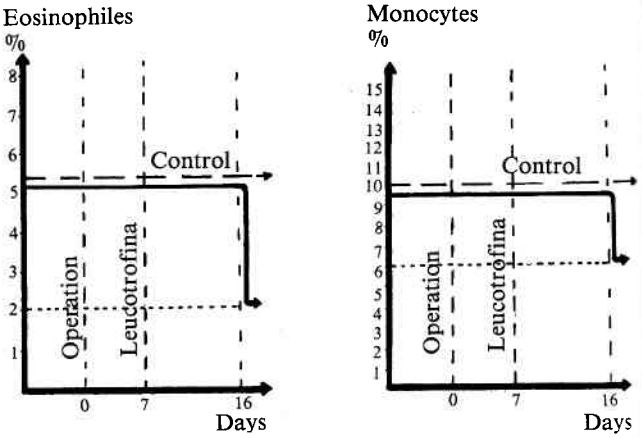

Fig. 2.

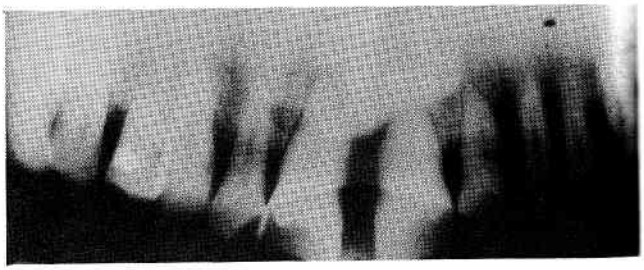

Fig. 3 A. — Clinical case No. 1. Patient K. M., aged 23, student. Dg.: Chronic marginal parodontitis with frontal, vertical bone atrophy, desmodontitis at 2.1 and mobility grade III at 2.1 and 1.1.

Fig. 3 B. — Radiologic aspect 3 years after composite therapy: gingivo-osteoplasty, transfixation with Scialom implant needle 2.1, 1.1, horizontal contention with Concise runner and adjuvant therapy with thymomodulin.

Fig. 4A and B. — Clinical case No. 2. Patient C. D., aged 33, engineer. Dg.: Chronic mixed parodontopathy with septal alveolysis between 1.2 and 1.3. A) Gingival retraction of 3 mm at 1.3. Retrograde periapical chronic osteitis in suppurated acute stage. B) Radiologic aspect 2 years after composite therapy: gingivo-osteoplasty with medullo-spongious autotransplant, apical resection of 1.3, immobilization with Concise runner and L splint at 1.2, 1.3 and adjuvant therapy with thymomodulin.

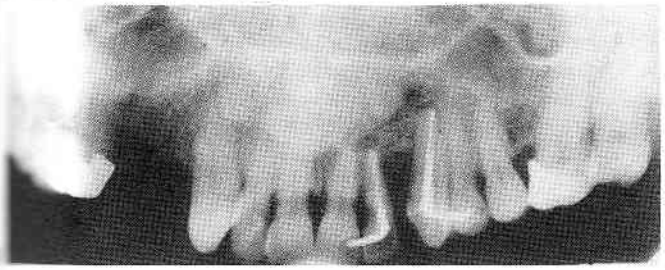

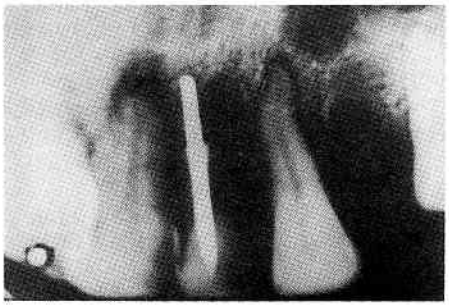

Fig. 5A. — Clinical case No. 3. Patient G. I., aged 28, technician. Dg.: Chronic marginal parodontitis, vertical bone atrophy at 2.2 with mobility grade III, fixed by transfixation with Scialom implant needle.

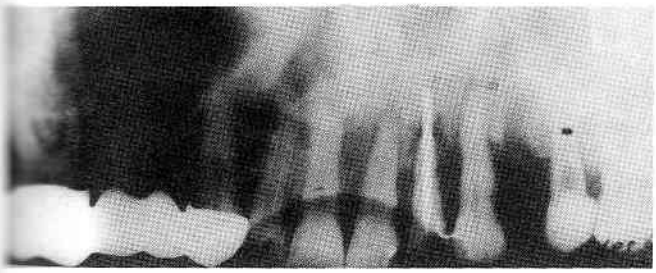

Fig. 5B. — Radiologic aspect 1.5 years after composite therapy: horizontal immobilization with «U» splint and adjuvant therapy with thymomodulin.

A qualitative modulatory effect of thymomodulin was obtained on leukogram in operated dystrophic-inflammatory parodontopathy 10 days after thymomodulin treatment, the eosinophile and monocyte counts returning to the normal values, showing the control of the allergic component, reestablishment of the phagocytic function and modulation of the reticulo-endothelial system (Fig. 2).

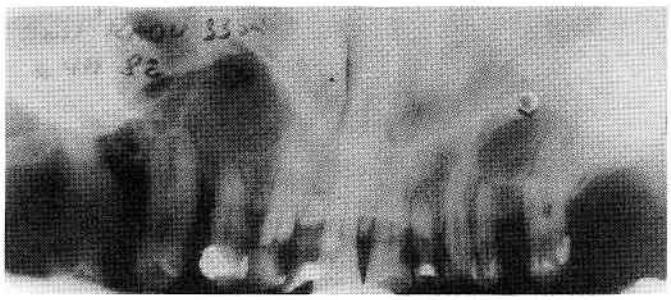

Fig. 6A. — Clinical case No. 4. Patient D. R., aged 33, technician. Dg.: Chronic marginal parodontitis with vertical bone atrophy, multiple maxillary coronary destructions, dental mobility grade II/III.

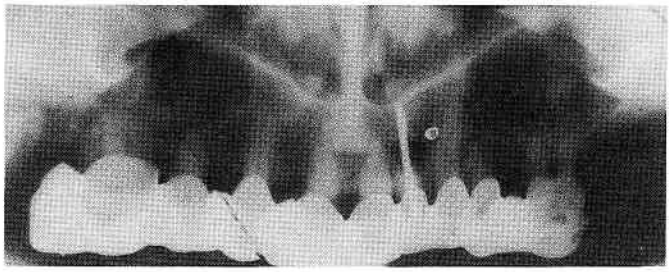

Fig. 6B. — Radiologic aspect 3 years after composite therapy: gingivo-osteoplasty with multiple maxillary extractions, dental transfixation at 2.2 with Scialom implant needls, plasty of radicular denudation at 1.3, 1.4 with obliquely rotated skin graft, horizontal immobilization with total semi-physionomic bridge and adjuvant therapy with thymomodulin.

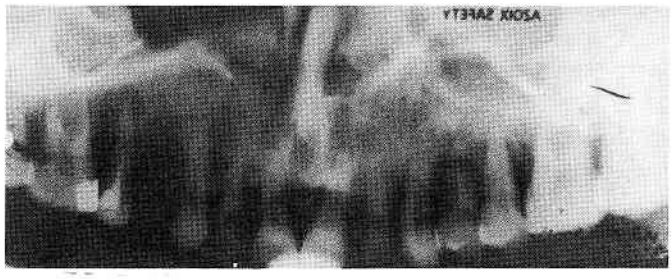

Fig. 7A. — Clinical case No. 7A. Patient D. R., aged 45, teacher. Dg.: Chronic marginal parodontosis with vertical bone atrophy and dental mobility grade II/III.

Fig. 7B. — Radiologic aspect 1.5 years after composite therapy: gingivo-osteoplasty with medullo-spongious autotransplants in the frontal region, contention with acrylate pericoronary runner and adjuvant therapy with thymomodulin.

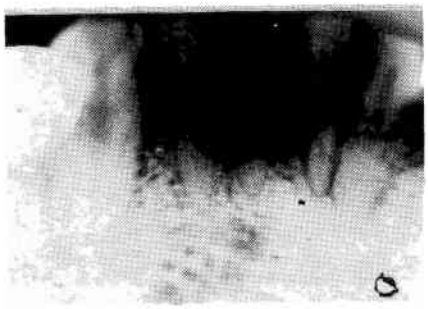

Fig. 8A. — Clinical case No. 6. Patient P. L., aged 43, teacher. Dg.: Chronic marginal parodontitis of frontal group, desmodentitis and dental mobility grade III at 3.1, Foci of halisteresis and adjacent osteoporosis.

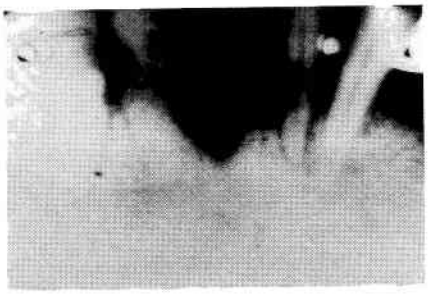

Fig. 8B. — Radiologic aspect 1 year after composite therapy: gingivo-osteoplasty with extraction of 3.1, conjoint physionomic prosthesis; adjuvant therapy with thymomodulin.

Conclusions

1) In chronic deep marginal parodontopathy and mixed parodontopathy with bone pouches the only therapeutic method remains gingivo-osteoplasty with spongious autogenous transplant associated with horizontal and vertical immobilizations (dental transfixation with needle implant, U,L splint, reinforced palatinal Concise runners, conjoint works and biostimulating therapy.

2) The late clinical-radiologic results 1, 2, 3 years after the surgical treatment of parodontopathy with bone pouches, associated with auxiliary treatment with thymomodulin «Ellem» (Milan, Italy) justify the wide use of this product, it exerting an immuno-myelo-regenerating effect in dento-maxillary bone surgery.

References

1. Ackermann R.: «Die Nadel Implantate». Ed. Bremen, 1969.
2. Chiricuta I., Crivii M. S., Uray Z.: «Repeuplement de la rate par des cellules fonctionnelles chez les souris irradiées sons l'effect de la Leucotrofine et du Polidin». Agressologie, 23, 3, 95, 1982.
3. Dajbukat F. R. jr.: «Chirurgie proprotetică si implantele endoosoase». Teza de doctorat, IMP Cluj-Napoca, 1980.
4. Firu P., Itcou R., Stanusescu A.: «Focarele dentàre în cadrul concepţiilor actuale». Al VIII-lea Curs de Stomatologie Infantilă Poiana Mărului, 1981. Culegere de Problemă, 31.
5. Gafar Memet: «Curs de terapie buco-dentară». IMF Bucureşti, 1973.
6. Nitescu M.: «Alveolar bone neoosteogenesis, its stimulation by ontogenous bone marrow and cancellous transplants». Acta Stomat. Internationalia, N. 3, Tome III, 170, 1981.
7. Perni E. M.: «Problemi implantologici nel dismetabolismo e nelle disendocrinie interessanti il tessuto osseo». Bollettino Odonto-implantologico. S.O.I.A. Italiana, 21, 27, 1973.
8. Rimbasiu M.: «Rezolvarea chirurgicală a pungilor osoase parodontale prin implante autogene de os alăturat». Stomatologia, Bucureşti, 3, 209, 1976.
9. Uray Z., Radulescu E., D. Suciu.: «The effect of thymic humoral factor (Leucotrofina) upon regeneration of haemopoietic and lymphatic tissues of irradiated mice». Panminerva Medica, 2, 21, 57, 1979.
10. Uray Z., Ban M., Bucur M., Carpen M.: «Valeur de la Leucotrofina comme adjuvant dans la radiothérapie antitumorale». Agressologie, Paris, 21, 4, 215, 1980.

Author's address: Dott. E. Mincione
Clinica Odontoiatrica dell'Università - 41100 Modena (Italy)